045-DermCase 4/17/07 2:28 PM Page 45

DermCase

Test your knowledge with multiple-choice cases

This month–8 cases:

1. *A Hyperpigmented Patch* p.45
2. *Inflamed Skin* p.46
3. *A Painful Rash* p.47
4. *Pruritic Lesions* p.49
5. *Yellowish Bumps* p.50
6. *"Tapioca-like" Vesicles* p.51
7. *Asymptomatic Lesions* p.52
8. *A Spreading Rash* p.53

Case 1

A Hyperpigmented Patch

A five-year-old boy is noted to have a solitary brownish patch on his body. The lesion is flat and has been present since birth.

What is your diagnosis?

a. Café-au-lait patch
b. Nevis spilus
c. Becker nevus
d. Mongolian spot

Answer

A café-au-lait patch **(answer a)** is a hyperpigmented, regularly bordered, sharply demarcated patch that is tan or light brown in white-skinned individuals and dark brown in dark-skinned individuals. The lesion is characterized by an increased number of melanocytes and by a corresponding increase in the amount of melanin in the epidermis.

Solitary café-au-lait spots are found in 3% to 10% of healthy children and have no clinical significance. The presence of five or more spots that are ≥ 0.5 cm in a prepubertal child, or of six or more spots that are > 1.5 cm in a postpubertal child is pathognomonic for neurofibromatosis Type 1. Café-au-lait spots are found with increased frequency in patients with Russell-Silver syndrome, tuberous sclerosis, Fanconi anemia, multiple endocrine neoplasia types 1 and 2B, Turner syndrome, Gaucher disease and chromosomal anomalies such as ring chromosome 7, 11, 12, 15 and 17. A large café-au-lait patch with a serrated border or midline demarcation suggests the possibility of McCune-Albright syndrome. In this condition, the café-au-lait patch is usually located on the same side as the bony abnormalities.

Copyright© Not for Sale or Commercial Distribution
Unauthorised use prohibited. Authorised users can download, display, view and print a single copy for personal use

Alexander K. C. Leung, MBBS, FRCPC, FRCP (UK & Irel), is a Clinical Associate Professor of Pediatrics, University of Calgary, Calgary, Alberta.

W. Lane M. Robson, MD, FRCPC, is the Medical Director of The Children's Clinic in Calgary, Alberta.

Tom Woo, MD, FRCPC, is a Dermatologist, University of Calgary, Calgary, Alberta.

Case 2

Inflamed Skin

A 47-year-old female presents with a six-month history of asymptomatic papules and annular plaques on the dorsal aspect of her hands. She is otherwise healthy. She has not had treatment for her condition.

What is your diagnosis?

a. Tinea manus
b. Nummular dermatitis
c. Granuloma annulare
d. Scabies
e. Contact dermatitis

Answer

Granuloma annulare **(answer c)** is a benign inflammatory skin condition characterized by erythematous, flesh-coloured dermal papules and annular plaques that are typically asymptomatic and without scale. It occurs in all age groups and has no racial predilection. Its cause is unknown. Granuloma annulare has been loosely associated with diabetes mellitus. The diagnosis is often made clinically and confirmed by biopsy. Histological examination reveals foci of degenerative collagen associated with palisaded granulomatous inflammation.

Spontaneous involution often occurs and no treatment is required for mild, localized cases. It is often reported that a biopsy of a particular lesion can cause its involution. Intralesional cortisone injections can be helpful in treating the condition. Topical steroids, cryotherapy and topical immunomodulators have shown anecdotal success. Various systemic treatments have been put forth for more generalized granuloma annulare, but none are uniformly successful.

It is often reported that a biopsy of a particular lesion can cause its involution.

Samir N. Gupta, MD, FRCPC, DABD, completed his Dermatology Fellowship training at Harvard University and currently practices in Toronto, Ontario with a special interest in Laser Dermatology.

045-DermCase 4/17/07 2:28 PM Page 47

Case 3

A Painful Rash

A 45-year-old man presents with a painful rash on his right forearm.

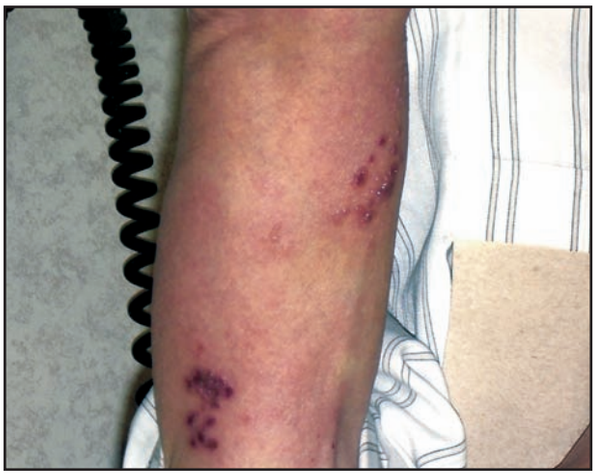

What is your diagnosis?

a. Herpes simplex
b. Herpes zoster
c. Molluscum contagiosum
d. Chickenpox

Answer

Herpes zoster **(answer b)**, or shingles, is caused by the reactivation of latent varicella-zoster virus that resides in a dorsal root ganglion. Herpes zoster can occur at any age, but the incidence is highest in those > 60-years-of-age. Varicella vaccine is a live attenuated virus and as such, herpes zoster can develop in a vaccine recipient. Herpes zoster is characterized by a group of hemorrhagic vesicles on an erythematous base that erupts unilaterally in the distribution of the dermatome that corresponds to the affected dorsal root ganglion. Pain within the affected dermatome often precedes the onset of the rash by two days to three days. An area of erythema might precede the development of the vesicles. Herpes zoster is more common and severe in individuals who are immunocompromized. Complications include:

- secondary bacterial infection,
- depigmentation,
- scarring and
- post-herpetic neuralgia.

In immunocompromized individuals, the lesions might develop in unusual dermatomes or in viscera. Other complications include:

- encephalitis,
- ventriculitis,
- sclerokeratitis,
- anterior uveitis,
- Ramsay Hunt syndrome and
- motor nerve paresis.

Patients with herpes zoster might benefit from oral antiviral therapy such as:

- acyclovir,
- valacyclovir, or
- famciclovir.

Alexander K. C. Leung, MBBS, FRCPC, FRCP (UK & Irel), is a Clinical Associate Professor of Pediatrics, University of Calgary, Calgary, Alberta.

W. Lane M. Robson, MD, FRCPC, is the Medical Director of The Children's Clinic in Calgary, Alberta.

Tom Woo, MD, FRCPC, is a Dermatologist, University of Calgary, Calgary, Alberta.

Case 4

Pruritic Lesions

This man presents with a mildly pruritic lesion, which he has had for a few months.

What is your diagnosis?

a. Facial psoriasis
b. Tinea
c. Contact dermatitis
d. Seborrheic dermatitis
e. Acne rosacea

Answer

Seborrheic dermatitis (SD) **(answer d)** of the face is often pruritic. Itching of the scalp, however, is a common symptom. There is erythema and fine, bran-like scaling on the forehead, nasolabial folds, around the ears and on eyebrows or eyelids.

The scalp is often involved, as well as presternal and intertriginous areas, such as the vault of the axilla and groin. Seborrheic blepharitis is SD of the eyelids and margins. The condition can be florid in AIDS patients.

Psoriasis has a typical pattern of distribution on the:

- elbows,
- knees,
- scalp and
- nails.

In tinea, lesions are more circumscribed and hyphae are seen under the microscope. The hallmark of candidiasis is intertriginous involvement. Contact dermatitis can be distinguished by history of offending agent and more pruritis. Rosacea patients have a history of flushing. Centro facial erythema is not accompanied by scales.

Diagnosis of SD is made on clinical distribution and response to therapy. It is worthwhile to look for evidence of SD on all possible body sites.

SD is a chronic and recurring condition and patients may treat themselves without supervision for long periods. Therefore, use only low potent topical corticosteroid ointments or creams. Antifungal creams of the imidazole or allylamines classes can also be effective but work more slowly. High-potent or supra-potent corticosteroid solutions are safe on the scalp for long periods. Medical shampoos should contain tar, zinc, sulfur, or salicylic acid. The antifungal shampoo, ketoconazole 2%, can be used twice weekly.

SD often recurs in times of stress, either physical or emotional. Seborrheic blepharitis can lead to recurring infections of the eyelids, with hordeolum and conjunctivitis.

Hayder Kubba graduated from the University of Baghdad, where he initially trained as a Trauma Surgeon. He moved to Britain, where he received his FRCS and worked as an ER Physician before specializing in Family Medicine. He is currently a Family Practitioner in Mississauga, Ontario.

Case 5

Yellowish Bumps

An elderly male presents with yellowish bumps on his toes that he says have been present for a number of years.

What is your diagnosis?

a. Multiple xanthomas
b. Seborrheic keratoses
c. Heberden nodes
d. Chronic tophaceous gout
e. Calluses

Answer

This is an example of chronic tophaceous gout **(answer d)**. After a decade or more of acute gouty attacks, patients typically enter a phase of chronic polyarticular gout that is characterized by persistently swollen and painful joints. Tophi, which may or may not be obvious on clinical examination, are accumulations of uric acid crystals in periarticular areas, osseous tissues, ligaments and even soft tissues. If not clinically obvious, they can often be demonstrated radiologically. Tophi are typically found at the small joints of hands and feet but can also occur in the helix of the ear, the olecranon, finger pads, Achilles tendon and at pressure points. The best treatment is prevention.

They are typically found at the small joints of hands and feet but can also occur in the helix of the ear, the olecranon, finger pads, Achilles tendon and at pressure points.

Eunice Chow, MD, is a Dermatology Resident, University of Alberta, Edmonton, Alberta

Mike Kalisiak, MD, BSc, is a Dermatology Resident, University of Alberta, Edmonton, Alberta.

Case 6

"Tapioca-like" Vesicles

A 33-year-old female presents with a three-week history of small deep-seated "tapioca-like" vesicles on the lateral aspects of her fingers and on her palms. She had a similar episode a few years ago. She is otherwise healthy, on no medications and there is no family history of skin problems.

What is your diagnosis?

a. Bullous pemphigoid
b. Atopic dermatitis
c. Allergic contact dermatitis
d. Dyshidrotic eczema
e. Psoriasis

Answer

Dyshidrotic eczema (also termed pompholyx) **(answer d)** is an idiopathic recurrent form of vesicular palmoplantar dermatitis. The etiology is multifactorial and includes:

- genetic factors,
- atopy,
- nickel sensitivity and
- stress.

Patients complain of severe pruritus of the hands and less commonly of the feet with sudden onset of small deep-seated vesicles (that are "tapioca" coloured) on the palms and lateral aspects of the digits. There are no burrows present unlike in scabies. Burning or pruritus may precede the onset of vesicles. Diagnosis is made clinically, although occasionally swabs for bacterial culture and sensitivity are warranted to rule out secondary infection.

Patients are typically treated with ultrapotent topical steroids (*e.g.*, clobetasol) until the rash clears and are advised to keep the treatment available for recurrences. Burow's solution can be soothing. Large bullae can be drained, allowing the roof to act as a natural barrier. Systemic steroids are required in more severe or extensive involvement and, less commonly, phototherapy is employed.

Benjamin Barankin, MD, FRCPC, is a Dermatologist in Toronto, Ontario.

045-DermCase 4/17/07 2:28 PM Page 51

Case 7

Asymptomatic Lesions

A 49-year-old Caucasian male presents with a several-year history of brown polypoid papules in his axillae and around his neck. These lesions are asymptomatic, although he is bothered by the appearance. There is no personal or family history of skin disease and he is otherwise healthy.

What is the diagnosis?

a. Neurofibromas
b. Acrochordons
c. Compound nevi
d. Seborrheic keratoses
e. Verruca vulgaris

Answer

Acrochordons **(answer b)** or skin tags are common, small, benign, pedunculated tumours, more frequently found in overweight individuals. These lesions are usually skin-coloured or hyperpigmented. Most acrochordons vary in size from 2 mm to 5 mm in diameter, although larger acrochordons up to 5 cm in diameter can appear. They are most commonly found around the neck and the axillae, but any skin fold, including the groin, may be affected. Diagnosis is clinical.

Treatment is usually cosmetic, although skin tags can become irritated by jewellery (*e.g.*, around neck) or rubbing (*e.g.*, inner thighs). Treatment is by destructive means, including:

- snip-excision,
- electrodesiccaton, or
- liquid nitrogen cryotherapy.

Treatment is by destructive means including snip-excision, electrodesiccaton, or liquid nitrogen cryotherapy.

Benjamin Barankin, MD, FRCPC, is a Dermatologist in Toronto, Ontario.

Case 8

A Spreading Rash

This 40-year-old patient has been hospitalized and bedridden for several weeks. Over the past two weeks, she developed a spreading rash on her thighs and buttocks. Among her many medications, she received broad-spectrum antibiotics.

What is your diagnosis?

a. Impetigo
b. *Cutaneous candidiasis*
c. Inverse psoriasis
d. Intertrigo
e. Allergic contact dermatitis

Answer

Cutaneous candidiasis or candidosis **(answer b)** has a predilection for moist, macerated and occluded areas of the skin. Intertrigo and diaper dermatitis are probably the most common presentations. *Decubital candidosis* is one of the names given to an infection affecting backs of bedridden patients and on average, occurs about four weeks into hospitalization and is facilitated by antibiotic use.

The clinical appearance of *cutaneous candidiasis* is characterized by appearance of vesicopustules that break open to expose an intensely erythematous base surrounded by a collarette of dead epidermis. Presence of satellite lesions is one of the most characteristic findings. There is often associated pruritus. Diagnosis can be confirmed with KOH examination or culture.

Cutaneous candidiasis can usually be treated with topical nystatin or imidazole antifungals. Addition of a mild corticosteroid, such as hydrocortisone, helps relieve pruritus and burning. In cases of extensive infections or where frequent application of topicals is impractical, oral azoles such as fluconazole may be indicated.

Cutaneous candidiasis can usually be treated with topical nystatin or imidazole antifungals.

Mike Kalisiak, MD, BSc, is a Dermatology Resident, University of Alberta, Edmonton, Alberta